

Osteoarthritis and Cartilage



Brief Report

Exosomes derived from human embryonic mesenchymal stem cells promote osteochondral regeneration



S. Zhang †, W.C. Chu †, R.C. Lai ‡, S.K. Lim ‡§, J.H.P. Hui ||¶, W.S. Toh †¶*

† Faculty of Dentistry, National University of Singapore, Singapore

‡ Institute of Medical Biology, Agency for Science, Technology and Research, Singapore

§ Department of Surgery, Yong Loo Lin School of Medicine, National University of Singapore, Singapore

|| Cartilage Repair Program, Therapeutic Tissue Engineering Laboratory, Department of Orthopaedic Surgery, National University Health System, National University of Singapore, Singapore

¶ Tissue Engineering Program, Life Sciences Institute, National University of Singapore, Singapore

ARTICLE INFO

Article history:

Received 22 February 2016

Accepted 28 June 2016

Keywords:

Human

Mesenchymal stem cells

Exosomes

Cartilage

Osteochondral

Regeneration

SUMMARY

Objective: Clinical and animal studies have demonstrated the efficacy of mesenchymal stem cell (MSC) therapies in cartilage repair. As the efficacy of many MSC-based therapies has been attributed to paracrine secretion, particularly extracellular vesicles/exosomes, we determine here if weekly intra-articular injections of human embryonic MSC-derived exosomes would repair and regenerate osteochondral defects in a rat model.

Methods: In this study, osteochondral defects were created on the trochlear grooves of both distal femurs in 12 adult rats. In each animal, one defect was treated with 100 µg exosomes and the contralateral defect treated with phosphate buffered saline (PBS). Intra-articular injections of exosomes or PBS were administered after surgery and thereafter weekly for a period of 12 weeks. Three unoperated age-matched animals served as native controls. Analyses were performed by histology, immunohistochemistry, and scoring at 6 and 12 weeks after surgery.

Results: Generally, exosome-treated defects showed enhanced gross appearance and improved histological scores than the contralateral PBS-treated defects. By 12 weeks, exosome-treated defects displayed complete restoration of cartilage and subchondral bone with characteristic features including a hyaline cartilage with good surface regularity, complete bonding to adjacent cartilage, and extracellular matrix deposition that closely resemble that of age-matched unoperated control. In contrast, there were only fibrous repair tissues found in the contralateral PBS-treated defects.

Conclusion: This study demonstrates for the first time the efficacy of human embryonic MSC exosomes in cartilage repair, and the utility of MSC exosomes as a ready-to-use and 'cell-free' therapeutic alternative to cell-based MSC therapy.

© 2016 The Author(s). Published by Elsevier Ltd on behalf of Osteoarthritis Research Society International. This is an open access article under the CC BY-NC-ND license (<http://creativecommons.org/licenses/by-nc-nd/4.0/>).

Introduction

Adult articular cartilage has limited capacity for regeneration upon injury¹. Current treatment modalities such as mosaicplasty

and autologous chondrocyte implantation suffer issues of donor site morbidity and often generate inferior fibrocartilage repair². Therefore, alternative cell sources such as stem cells are being investigated for cartilage repair².

In recent years, advances in stem cell research have led to promising stem cell-based therapies for cartilage repair³. Notably, adult mesenchymal stem cells (MSCs) have been applied in laboratory^{4,5} and clinical studies⁶ for cartilage repair. However, cartilage repair by adult MSCs is not optimal⁵ and is hindered by limited cellular capacity for self-renewal, proliferation and differentiation with increasing donor age³. Human pluripotent stem cells (hPSCs) represent a promising cell source for regenerative medicine due to

* Address correspondence and reprint requests to: W.S. Toh, Faculty of Dentistry, National University of Singapore, 11 Lower Kent Ridge Road, Singapore 119083, Singapore. Tel: 65-6779-5555x1619; Fax: 65-6778-5742.

E-mail addresses: a0136456@u.nus.edu (S. Zhang), dencwc@nus.edu.sg (W.C. Chu), ruennchai.lai@imb.a-star.edu.sg (R.C. Lai), saikiang.lim@imb.a-star.edu.sg (S.K. Lim), james_hui@nuhs.edu.sg (J.H.P. Hui), dentohws@nus.edu.sg, tohweiseong@yahoo.com.sg (W.S. Toh).

their unlimited self-renewal capacity and ability to differentiate into various lineages, including chondrogenic lineage. However, the clinical potential of hPSCs is hampered by issues of tumorigenicity, genomic stability and immunogenicity^{7,8}. As with all cell-based therapies, there exist significant logistic and operational challenges associated with proper handling and cell storage required to maintain cell viability and vitality. Therefore, in view of all these issues, there is a need to develop a strategy to overcome the disadvantages of a cell-based therapy.

Increasingly, the efficacy of many MSC-based therapies has been attributed to the paracrine secretion of trophic factors, and that exosomes play a major role in mediating tissue repair. Exosomes are cell-secreted bi-lipid membrane, nano-sized vesicles of about 50–100 nm present in the MSC secretome⁹ and have been demonstrated in recent studies to have therapeutic effects in facilitating tissue repair in heart⁹, liver¹⁰ and skin¹¹. The implication of these findings to cartilage repair is unclear. To our knowledge, the effect of MSC exosomes on cartilage regeneration has not been investigated.

We hypothesized that MSC exosomes could promote osteochondral regeneration. Therefore, in the setting of an established rat osteochondral defect model¹², the effects of weekly intra-articular injections of human embryonic MSC-derived exosomes on repair of osteochondral defects were studied.

Methods

Preparation of MSC exosomes

MSCs were derived from HuES9 human embryonic stem cells (hESCs)¹³, and used for the production of MSC-conditioned medium (MSC-CM). Following our established protocol, exosomes were purified from the MSC-CM and stored at -20°C until use⁹.

Western blotting

Western blotting was performed following standard protocol. Briefly, 20 μg proteins were separated on polyacrylamide gels, electroblotted onto a nitrocellulose membrane and probed with primary antibody followed by horseradish peroxidase (HRP)-coupled secondary antibody against the primary antibody. As described in [Supplementary Table 1](#), the primary antibodies used were mouse anti-human CD81, ALIX and TSG101 (Santa Cruz Biotechnology, Dallas, TX). The labelled proteins were visualized with ChemiDoc™ XRS imaging system using chemiluminescence.

Size determination

The size distribution of exosomes was measured by NanoSight LM10 (Malvern, Worcestershire, UK) and analysed by Nanoparticles Tracking Analysis software (Malvern) according to the manufacturer's protocol.

Detection of RNA

100 μg of exosomes were extracted for RNA using Trizol LS reagent and quantitated using Quanti-TTM RiboGreen RNA Assay Kit (ThermoFisher Scientific). 200 ng exosomal RNAs were then resolved on a 15% Novex Tris–borate–EDTA (TBE)–urea gels before staining with ethidium bromide.

Animal experiments

All procedures were performed according to the Institutional Animal Care and Use Committee at National University of Singapore

under protocol number: R14-913. Critical-sized osteochondral defects (1.5-mm diameter and 1-mm depth) were created on trochlear grooves of the distal femurs of twelve 8-week-old Sprague Dawley (SD) female rats¹². The animals were randomly allocated to two groups: defects treated with 100 μg exosomes ($n = 12$) and contralateral control defects treated with phosphate buffered saline (PBS) vehicle ($n = 12$). Intra-articular injections of exosomes (100 μg exosomes per 100 μl injection) or PBS control (100 μl) were administered after surgery and subsequently on a weekly basis. Three unoperated animals at 12 weeks served as age-matched native controls. Animals were allowed to move freely in the cage after surgery with access to food and water.

Gross appearance and histological evaluation

At 6 and 12 weeks, animals were euthanized and distal femora were resected *en bloc*. Gross appearance was graded by three independent blinded observers according to the International Cartilage Repair Society (ICRS) macroscopic assessment, including parameters of degree of defect repair, integration to border zone and macroscopic appearance for cartilage repair, with a maximum score of 12. After gross examination, samples were processed for histology. Serial sections were cut at 5- μm and stained with haematoxylin and eosin (HE) and safranin-O/fast green (Saf-O). Immunohistochemical staining for type I, II, VI and X collagens, and lubricin was also performed¹² ([Supplementary Table 1](#)). The quality of cartilage repair was assessed using the modified O'Driscoll histologic scoring system by three blinded independent observers for parameters including cellular morphology, matrix staining, surface regularity, structural integrity, thickness, bonding, and freedom from cellular changes of degeneration with a maximum score of 27¹⁴.

Statistical analysis

All quantitative data were reported as mean (95% confidence interval (CI)). Differences were determined by unpaired two-tailed Student *t* test using Statview software version 5 (SAS Institute Inc., Cary, NC). Statistical significance was set as $P < 0.05$.

Results

Characterization of MSC exosomes

The exosomes purified from MSC-CM carried exosome-associated markers, CD81, TSG101 and ALIX as shown by western blotting [[Supplementary Fig. 1\(A\)](#)]. This exosome preparation contained homogeneously sized particles with a modal size of 100 nm [[Supplementary Fig. 1\(B\)](#)]. It also contained RNA, most of which are less than 300 nucleotides [[Supplementary Fig. 1\(C\)](#)]. Therefore, the exosome preparation used in this study qualified as exosome as it possessed all the defining characteristics of exosomes, a specific type of extracellular vesicles⁹.

Effect of MSC exosomes on repair of full-thickness cartilage defects

We assessed the effect of MSC exosomes on the repair of critical-sized osteochondral defects in a rat model. In each animal, one defect was treated with exosomes and the contralateral defect treated with PBS. At 6 and 12 weeks, the distal femurs were harvested for analysis.

Macroscopically, all defects treated with exosomes showed moderate to good neotissue filling, moderate surface regularity and good integration with the host cartilage at 6 weeks. Conversely, contralateral control defects displayed irregular surface regularity

with structural disruptions and fissures [Fig. 1(A)]. The ICRS macroscopic assessment was 9.2 (95% CI, 6.7–11.6) in exosome-treated defects and 8.0 (95% CI, 6.7–9.2) in the PBS-treated defects, with no significant difference [$P = 0.29$; Fig. 1(B)].

Histologically at 6 weeks, all exosome-treated defects showed complete neotissue filling. Four out of six exosome-treated defects showed good surface regularity, while the remaining two defects had a few fissures on the surface. Four out of six exosome-treated defects also showed hyaline cartilage formation characterized by uniform distribution of high amounts of glycosaminoglycan (GAG) and type II collagen, and low amount of type I collagen [Fig. 1(C)]. The remaining two defects demonstrated partial areal staining (<50%) for GAG and type II collagen at a relatively lower intensity. Under high magnification, majority of the cells (>70%) appeared

chondrocytic (i.e., spherical with lacuna) and displayed pericellular matrix staining of type VI collagen. Four out of six exosome-treated defects further showed complete subchondral bone regeneration. On the contrary, PBS-treated defects showed mostly fibrous tissue that stained intensely for type I collagen, but minimally for GAG and type II collagen. Four out of six PBS-treated defects further showed poor reconstitution of subchondral bone. At 6 weeks, the modified O'Driscoll score revealed a significant difference in degree of repair: 22.5 (95% CI, 17.5–27.6) in exosome-treated group compared to 14.0 (95% CI, 10.8–17.2) in PBS-treated group [$P = 0.004$; Fig. 1(D)].

At 12 weeks, the exosome-treated defects showed almost complete neotissue coverage with good surface regularity and complete integration with the surrounding cartilage. Conversely,

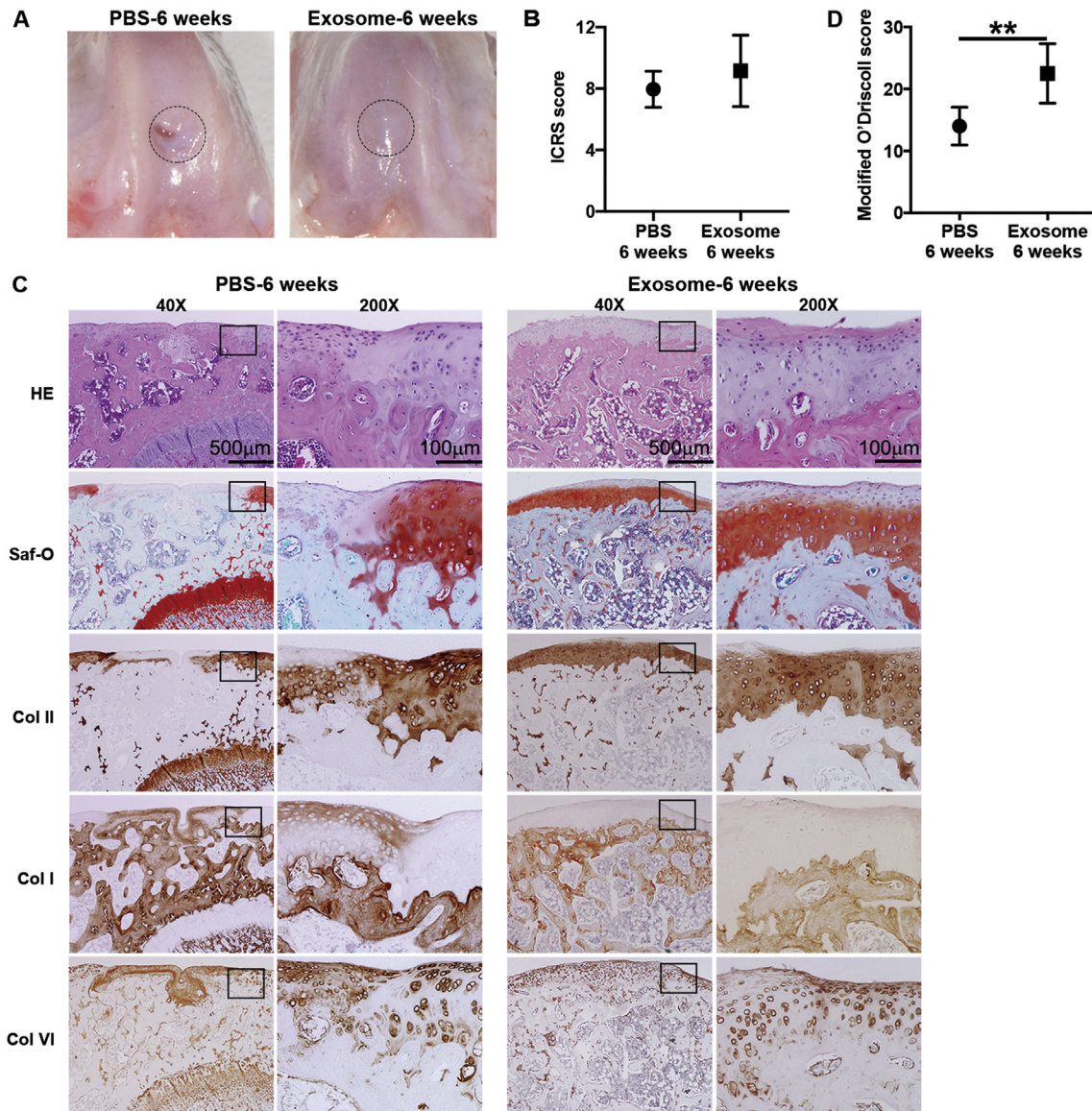


Fig. 1. *In vivo* cartilage repair at 6 weeks post-surgery. Osteochondral defects (1.5 mm diameter and 1 mm depth) were created on the trochlear grooves at both knees of SD rats. Exosome-treated defects were compared against the contralateral control defects treated with PBS. (A) Representative gross morphologies. (B) ICRS macroscopic scores. Values represent the means \pm 95% CI. P -values were determined by unpaired two-tailed Student t test ($n = 6$ per group). (C) Staining results of HE and Saf-O, and immunohistochemical staining for type II, I and VI collagens. (D) Modified O'Driscoll histologic scores for cartilage repair at 6 weeks. Values represent means \pm 95% CI. P -values were determined by unpaired two-tailed Student t test ($n = 6$ per group). The results of histologic scores showed that the defects treated with MSC exosomes produced better repair than the control defects at 6 weeks. Exosome treatment (100 μ g per 100 μ l injection on a weekly basis) induced significant cartilaginous neotissue with comparable matrix staining and structural integration to the adjacent host cartilage. Comparatively, PBS-treated defects showed mostly fibrous and non-cartilaginous tissue. Histological scoring showed significant difference in the repair of osteochondral defects between the groups ($P = 0.004$).

the contralateral control defects treated with PBS showed incomplete neotissue filling, surface irregularity and distinct border areas [Fig. 2(A)]. The ICRS macroscopic score was 9.7 (95% CI, 8.2–11.2) in exosome-treated group and 8.6 (95% CI, 7.4–9.8) in PBS-treated group, with no significant difference [$P = 0.15$; Fig. 2(B)].

Histologically, five out of six exosome-treated defects showed smooth hyaline cartilage formation with matrix staining that was comparable to that of native cartilage while the remaining one defect demonstrated fibrocartilaginous tissue repair. Specifically, the exosome-treated tissues exhibited uniform and intense staining of GAG (>80%), high level of type II collagen, and low level of type I collagen, indicative of hyaline cartilage. Except for some areas near the subchondral bone, exosome-treated tissues showed minimal hypertrophy with low level of type X collagen. Under high magnification, almost 100% of cells in the repaired tissue appeared chondrocytic, and displayed pericellular matrix staining of type VI collagen. Additionally, lubricin positive cells were found in the superficial and middle zones of the reparative cartilage, although a

clear zonal organization was not presented (Supplementary Fig. 2). All exosome-repaired tissues showed good bonding to adjacent cartilage and underlying subchondral bone. Five out of six exosome-treated defects showed complete regeneration of subchondral bone, with the exception of one defect showing partial reconstitution (>50%) with active tissue remodelling in process [Fig. 2(C)]. In contrast, there were only fibrous tissues found in PBS-treated defects, indicated by high amount of type I collagen, and absence of GAG and type II collagen. Four out of six PBS-treated defects further showed severe surface irregularity. In addition, three out of six PBS-repaired tissues showed hypocellularity and chondrocyte clusters (<25%), indicative of degenerative changes. At high magnification, cells in the fibrous tissue showed perfused inter-territorial/territorial distribution of type VI collagen. At 12 weeks, the modified O'Driscoll score revealed a highly-significant difference in the degree of repair: 23.5 (95% CI, 20.2–26.8) for exosome-treated group compared to 12.7 (95% CI, 11.3–14.1) in PBS-treated group [$P < 0.001$; Fig. 2(D)].

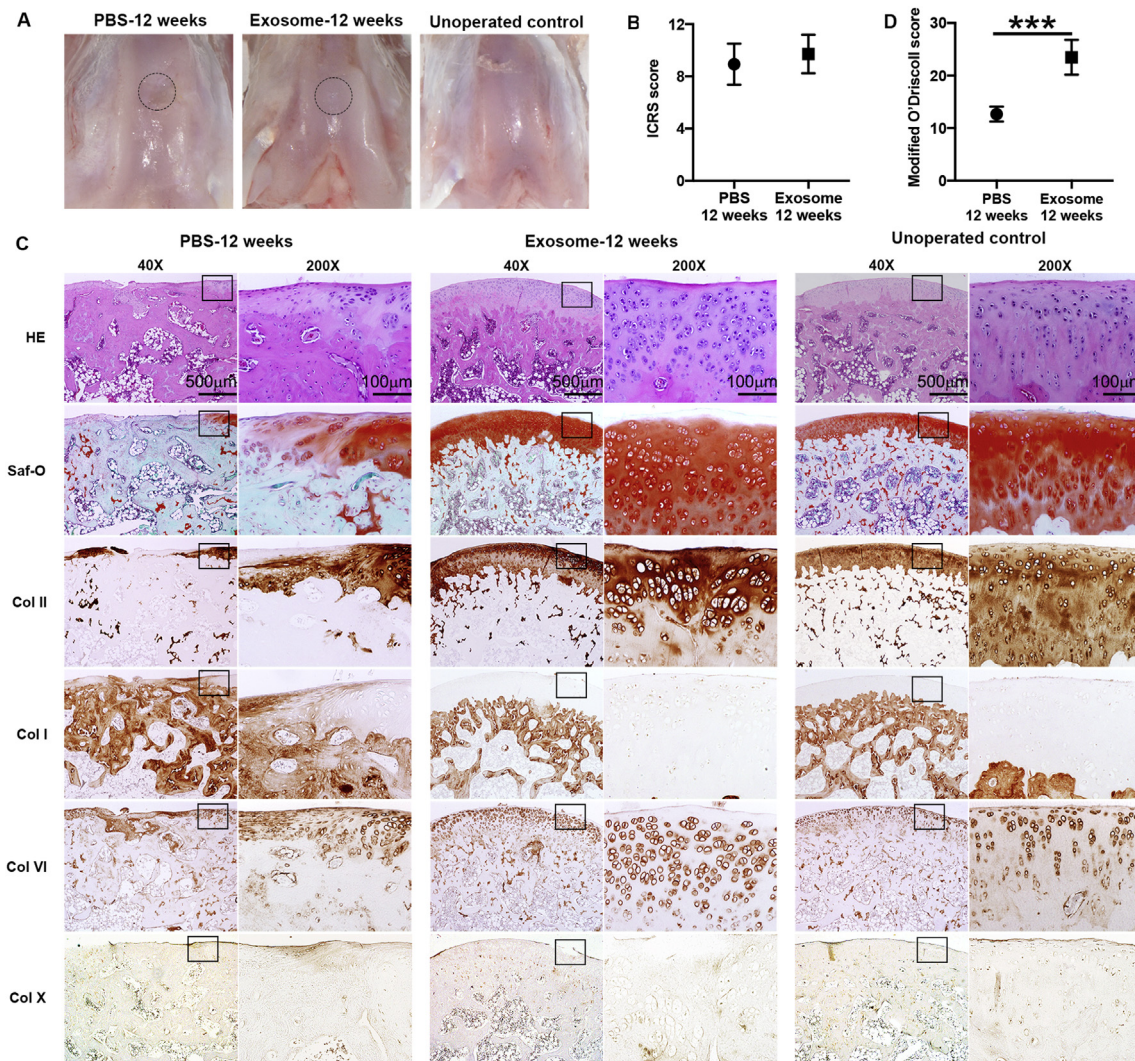


Fig. 2. *In vivo* cartilage repair at 12 weeks post-surgery. Exosome-treated defects were compared against the contralateral control defects treated with PBS and unoperated native control. (A) Representative gross morphologies. (B) ICRS macroscopic scores. Values represent the mean \pm 95% CI. *P*-values were determined by unpaired two-tailed Student *t* test ($n = 6$ per group). (C) Staining results of HE and Saf-O, and immunohistochemical staining for type II, I, VI and X collagens. (D) Modified O'Driscoll histologic scores for cartilage repair at 12 weeks. Values represent means \pm 95% CI. *P*-values were determined by unpaired two-tailed Student *t* test ($n = 6$ per group). By the end of 12 weeks, exosome-treated group showed a new cartilage layer with good surface regularity and structural integration. The regenerated neocartilage layer appeared hyaline with comparable matrix staining to the age-matched native cartilage. There was also complete subchondral bone regeneration. Histologic scoring showed significant difference in the repair of osteochondral defects between the groups ($P < 0.001$).

Discussion

Our study demonstrates for the first time that weekly intra-articular administration of human embryonic MSC exosomes promote repair of critical-sized osteochondral defects in an adult immunocompetent rat model.

Increasingly, there are supporting studies that showed the trophic effects of MSCs in facilitating tissue regeneration without the need of cellular differentiation and/or long-term engraftment^{9,10}. Among the trophic factors present in the secretome, exosomes play a major role in mediating the paracrine effects of MSCs^{9–11}. Comparing to cellular therapies, MSC exosome therapies offer advantages of being cell-free, ready-to-use and more amenable to reformulation to support different routes of administration.

We demonstrated in this study that weekly intra-articular injections of human embryonic MSC exosomes induced an orderly regeneration of cartilage and subchondral bone over a period of 12 weeks. The timeframe of up to 12 weeks was selected based on our prior study where a time period of 12 weeks is sufficient to observe a full reparative response in a rat model¹². By the end of 12 weeks, defects treated with exosomes showed a good regeneration with hyaline cartilage and underlying subchondral bone that closely resembled that of age-matched native control, while only fibrous and non-cartilaginous tissues filled in the contralateral control defects treated with PBS.

Previous studies demonstrated that human MSC exosomes do not have major histocompatibility complex (MHC) class I/II proteins, thereby enabling their application in immunocompetent animals without the need for immunosuppression^{9–11}. It has been established that xenotransplantation of human embryonic MSCs in immunocompetent animals for cartilage repair induces immediate adverse tissue reaction, resulting in poor reparative outcomes⁸. In this study, no adverse inflammatory response was observed in all animals, supporting the potential application of human MSC exosomes in allogeneic human recipients.

We have previously showed that MSC exosomes contain many regulatory components including microRNAs (miRNAs), mRNAs, and proteins that are likely to be mediators in cell–cell communications to induce changes in cell functions and processes¹⁵. Although the exact component(s) is yet to be elucidated, it is plausible that a myriad of components present in the MSC exosomes are needed to orchestrate tissue regeneration including cartilage and bone repair in this instance. Nevertheless, future studies would need to dissect the components present in MSC exosomes and to investigate their underlying mechanisms in cartilage repair.

Collectively, this proof-of-concept study demonstrates a ready-to-use and ‘cell-free’ strategy of utilizing human embryonic MSC exosomes for cartilage repair, that greatly overcome the impeding limitations of current cell-based therapies.

Author contributions

Conception and design (WST).
Acquisition of data (SZ, WCC, RCL).
Analysis and interpretation of data (SZ, WCC, RCL, SKL, JHH, WST).
Drafting of the article (SZ, WCC, RCL, SKL, JHH, WST).
Final approval of the article (SZ, WCC, RCL, SKL, JHH, WST).

Competing interests

The authors report that they have no conflicts of interest in the authorship and publication of this article.

Role of the funding source

This work was supported by grant from National Medical Research Council Singapore (R221000080511).

Acknowledgement

We thank Dr Xiafei Ren for guidance in rodent surgery, and help in the macroscopic and histological scorings.

Supplementary data

Supplementary data related to this article can be found at <http://dx.doi.org/10.1016/j.joca.2016.06.022>.

References

- Hunziker EB. Articular cartilage repair: basic science and clinical progress. A review of the current status and prospects. *Osteoarthritis Cartilage* 2002;10:432–63.
- Jiang YZ, Zhang SF, Qi YY, Wang LL, Ouyang HW. Cell transplantation for articular cartilage defects: principles of past, present, and future practice. *Cell Transplant* 2011;20:593–607.
- Toh WS, Foldager CB, Pei M, Hui JH. Advances in mesenchymal stem cell-based strategies for cartilage repair and regeneration. *Stem Cell Rev* 2014;10:686–96.
- Wakitani S, Goto T, Pineda SJ, Young RG, Mansour JM, Caplan AI, et al. Mesenchymal cell-based repair of large, full-thickness defects of articular cartilage. *J Bone Joint Surg Am* 1994;76:579–92.
- Shapiro F, Koide S, Glimcher MJ. Cell origin and differentiation in the repair of full-thickness defects of articular cartilage. *J Bone Joint Surg Am* 1993;75:532–53.
- Wong KL, Lee KB, Tai BC, Law P, Lee EH, Hui JH. Injectable cultured bone marrow-derived mesenchymal stem cells in varus knees with cartilage defects undergoing high tibial osteotomy: a prospective, randomized controlled clinical trial with 2 years' follow-up. *Arthroscopy* 2013;29:2020–8.
- Toh WS, Lee EH, Cao T. Potential of human embryonic stem cells in cartilage tissue engineering and regenerative medicine. *Stem Cell Rev* 2011;7:544–59.
- Zhang S, Jiang YZ, Zhang W, Chen L, Tong T, Liu W, et al. Neonatal desensitization supports long-term survival and functional integration of human embryonic stem cell-derived mesenchymal stem cells in rat joint cartilage without immunosuppression. *Stem Cells Dev* 2013;22:90–101.
- Lai RC, Arslan F, Lee MM, Sze NS, Choo A, Chen TS, et al. Exosome secreted by MSC reduces myocardial ischemia/reperfusion injury. *Stem Cell Res* 2010;4:214–22.
- Tan CY, Lai RC, Wong W, Dan YY, Lim SK, Ho HK. Mesenchymal stem cell-derived exosomes promote hepatic regeneration in drug-induced liver injury models. *Stem Cell Res Ther* 2014;5:76.
- Zhang B, Yin Y, Lai RC, Tan SS, Choo AB, Lim SK. Mesenchymal stem cells secrete immunologically active exosomes. *Stem Cells Dev* 2014;23:1233–44.
- Toh WS, Lee EH, Guo XM, Chan JK, Yeow CH, Choo AB, et al. Cartilage repair using hyaluronan hydrogel-encapsulated human embryonic stem cell-derived chondrogenic cells. *Biomaterials* 2010;31:6968–80.
- Lian Q, Lye E, Suan Yeo K, Khia Way Tan E, Salto-Tellez M, Liu TM, et al. Derivation of clinically compliant MSCs from CD105+, CD24– differentiated human ESCs. *Stem Cells* 2007;25:425–36.

14. Frenkel SR, Bradica G, Brekke JH, Goldman SM, Ieska K, Issack P, et al. Regeneration of articular cartilage – evaluation of osteochondral defect repair in the rabbit using multiphasic implants. *Osteoarthritis Cartilage* 2005;13:798–807.
15. Chen TS, Lai RC, Lee MM, Choo AB, Lee CN, Lim SK. Mesenchymal stem cell secretes microparticles enriched in pre-microRNAs. *Nucleic Acids Res* 2010;38:215–24.